



Customized Acetabular Labrum Mold Using a 3D Printing 3D Baskı Kullanarak Kişiyi Özel Asetabular Labrum Kalıbı

¹Bugra Husemoglu, ²Belma Nalbant, ¹Mehmet Dilsiz, ³Hasan Havitcioglu

¹Dokuz Eylül University, Institute of Health Sciences, Department of Biomechanics, Izmir, Turkey

²Dokuz Eylül University, Institute of Health Sciences, Department of Molecular Medicine Izmir, Turkey

³Dokuz Eylül University, Faculty of Medicine, Department of Orthopedics and Traumatology, Izmir, Turkey

Abstract: Labral disorders usually occur after trauma, tumour resections, infection and congenital defects. The purpose of labral repair is to protect the underlying pelvis, to reduce any localized pain. Acetabular labrum dissection is a frequent in ortopedical procedure. In this study achieved with the aid of labral prosthesis made from materials such as: synthetic cartilage. Prosthesis production is often costly and requires complex intraoperative processes. Implant customized manufacturing for labral constructs allows for a precise and anatomical reconstruction in a shorter operating time compared to other conventional techniques. We present a, patient-specific method for acetabular labrum mold that ensures surgical success. Patients with labral tears are presented to describe the three-dimensional (3D) printing technique for reconstruction. The Labrum model is designed and manufactured with the help of 3D computed tomography. Both the upper and lower labral model sides were transferred to a 3D printer to obtain a physical model of poly-lactic acid; this was then used in a laboratory to pour the final customized prosthesis in silicone. The exact fit of the labral mold with the labral defect was achieved. Customized 3D labral mold; anatomically appropriate, cost-effective, effective results. In this study, we demonstrated that 3D printing is a clinically highly applicable and easy to use technology for treating anatomically complex geometries.

Keywords: acetabular labrum, labrum molding, labral tears, 3D labrum

Husemoglu RB, Nalbant B, Dilsiz M, Havitcioglu, 2019 Customized Acetabular Labrum Mold Using a 3D Printing, *Journal of Medical Innovation and Technology*

Özet: Labral bozukluklar genellikle travma, tümör rezeksiyonları, enfeksiyon ve konjenital defektlerden sonra ortaya çıkar. Labral onarımın amacı, lokalize ağrıyı azaltmak için alt kısımdaki pelvisi korumaktır. Asetabular labrum diseksiyonu ortopedik prosedürde sık görülür. Bu çalışmada, sentetik kıkırdak benzeri malzemelerden yapılan labral protez oluşumu değerlendirilmiştir. Protez üretimi genellikle maliyetlidir ve karmaşık intraoperatif işlemler gerektirir. Labral yapılar için özel implant üretimi, diğer geleneksel tekniklere kıyasla daha kısa bir operasyon zamanı hassas ve anatomik rekonstrüksiyon sağlar. Çalışmada asetabular labrum yırtıkları için cerrahi başarı sağlayan, hastaya özel bir yöntem sunulmaktadır. Labral yırtığı olan hastalar rekonstrüksiyon için üç boyutlu (3D) baskı tekniğini tanımlamak için sunulmuştur. Labrum modeli 3B bilgisayarlı tomografi yardımı ile tasarlanmış dijitalize edilmiş ve üretilmiştir. Hem üst hem alt labral kısımlar, 3 boyutlu bir yazıcıya aktararak poli-laktik asitte fiziksel bir model elde edildi; bu, daha sonra silikonda son özelleştirilmiş protezi dökmek için bir laboratuvarında kullanıldı. Labral kalıbın labral defekt ile tam uyumu sağlandı. Kişiyi özel 3D labral kalıp anatomik olarak uygun, maliyet bakımından avantajlı, iyi bir sonuç sunmuştur. Bu çalışmada, 3D baskının anatomik olarak karmaşık geometrileri tedavi etmek için klinik açıdan son derece uygulanabilir ve kullanımı kolay bir teknoloji olduğunu gösterdik.

Anahtar Kelimeler: asetabular labrum, labrum kalıplama, labral gözyaşı, 3D labrum

Hüsemoglu R B, Nalbant B, Dilsiz M, Havitcioglu 2019. 3D Baskı Kullanarak Kişiyi Özel Asetabular Labrum Kalıbı, *Medikal İnovasyon ve Teknoloji Dergisi*

ORCID ID of the authors: B.H 0000-0003-1979-160X, B.N 0000-0002-2288-6979, M.D 0000-0002-5437-656X, H.H 0000-0001-8169-3539

Yazışma Adresi / Correspondence Address
Bugra HÜSEMOĞLU
mail: bugrahusem@gmail.com

1. Introduction

Preoperative imaging is important for the identification of pathologies and surgical planning (1). The most commonly used imaging for the evaluation of labroligamentous structures is intraarticular contrast-enhanced MR arthrography (2). However, computed tomography (CT) is used for imaging cartilages. The complex anatomy of the acetabulum and pelvis complicates the assessment and classification of acetabular labrum fractures. 3-dimensional (3D) labral models, preoperative

evaluation provides ease of anatomical navigation for surgeons (3).

3-dimensional model consists of three basic steps. The 3D printing procedure consists of 3D image reconstruction, digital preparation, and three dimensional printing. First, the patient's labral imaging is obtained using CT or magnetic resonance imaging (MRI). This 2D data is transferred to CAD software for 3D segmentation and visualization (Figür1). Finally, this data is transferred to the 3D printer to create a 3D labral model (1).

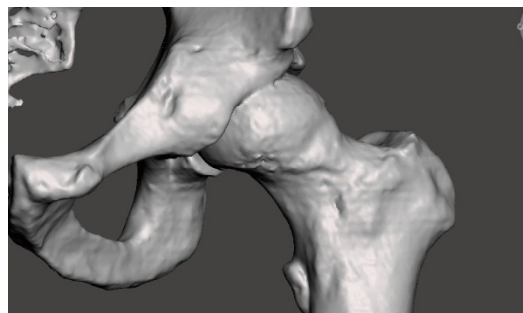


Figure 1. Patient specific Pelvis Model

Hurson et al. also created modeling studies to better understand the acetabular fractures, classification is related to the traditional classifications as well as proved the usability of screw and plate fixings. This technique will be a tool to help with complex trauma and orthopedic surgery (3).

Acetabular Labrum is a ring shaped soft tissue that surrounds the femur and is connected to pelvis. While it covers the femur head it reduces the stress caused by cartilage with the help of fluids it secretes (4). Even though Labrum has no major effect in sharing the load of the body it plays a bigger part in locating the femur to pelvis. Labrums form and fluids creates a vacuum around the femur head to seal it, letting both labrum and femur to resist forces that caused by the body and outer sources. With the help of this vacuum the load can distribute more efficiently across the body. Labrum nearly covers the whole acetabulum and femurs head, as a result more reduction on stress and strain that cartilage contact causes. However when the Labrum tears it becomes vulnerable (5).

Labral Tears usually occur after trauma, tumour resections, infection and congenital defects. The purpose of labral repair is to protect the underlying pelvis, to reduce any localized pain.

Acetabular labrum is a frequent neurosurgical procedure achieved with the aid of cranial prosthesis made from materials such as: synthetic cartilage. Prosthesis production is often costly and requires complex intraoperative processes. Implant customized manufacturing for labral constructs allows for a precise and anatomical reconstruction in a shorter operating time compared to other conventional techniques. We present a, patient-specific method for acetabular labrum mold that ensures surgical success (5).

Loss of a body part has significant repercussions for any individual. The absence of a body part has a great influence in a person's physical state and state of mind, and causes social interaction difficulty; which frequently limits their hope of recovery (6). For centuries, several materials have been tested to cover cartilage defects including coconut shells, allogenic and xenogenic soft tissue grafts, polymers and more recently, biosynthetic materials such as resins and collagens (7)

The ideal characteristics of prosthetic materials are their inability to cause inflammatory reactions, non-allergenicity or inability to cause hypersensitivity, chemical inertness, non-carcinogenicity, ability to withstand strain and

tension, capacity to be sterilized and to be molded into the desired shape when fabricated (8). Computer assisted design and prosthetic material modeling result in an excellent cosmetic outcome, and reduce operating time necessary for implant placement (9).

Synthetic implants are playing more and more important role in the supply for surgery. In this technical note, we present a case study of the use of 3D printing modeling total or local tissues have been presented in soft tissue like acetabular labrum.

2. Materials and Methods

Digital Design

The CT scan data is stored in the standard format DICOM (Digital Images and Communications in Medicine) which allows

generating an interface between the medical equipment and any other device to visualize the images. Through the DICOM viewer, 3D Slicer generated a three-dimensional reconstruction of all the CT cross-sectional images. A cartilage filter is applied in order to only observe the soft tissue structure, achieved by taking as reference its attenuation degree.

The construct is generated using the software of the computer-aided design (CAD) Meshmixer™ software (Autodesk, San Rafael, USA) since 3D Slicer is only a viewer. The mold piece is generated from the CT soft reconstruction of the patient's labrum (Fig.2). A boolean operation is applied to the volumes. The mold design must have a precise shape and volume according to each patient's pelvic anatomy. Finally, the data is exported in a stereolithography extension file (STL) and fed to the printer.

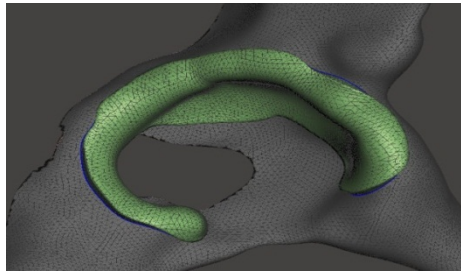


Figure 2. Patient specific Acetabular Labrum Construct

3D Printing

A custom made 3D printer (Dokuz Eylül University, Biomechanics Lab.) was used to print out a PLA mold from the STL file using a fused deposition model by means of a 1,75 mm filament at a 260 °C extruder temperature. Using polylactic acid (PLA) (0.15 mm layer thickness, 100 mm/s extrusion speed, 20% filling. Once the printing process is finished, which takes about 5 h.

The mold is an internal and an external surface

impression. A PLA mold silicone is poured into the space created by the internal plaster impression and pressed with the external mold. The casts are opened and the labrum is revealed after a 1 hour polymerization time. Precise anatomical compliance to the model is verified and approved by the multi-disciplinary team (including the orthopedions), and the labrum is then placed on a mannequin for academic and illustrative purposes (Fig. 3).



Figure 3. 3D Printed Acetabular Labrum Mold

3. Results

A patient acetabular labrum mold a with individually customized prefabricated molds generated from a 3D printed template. A

description of some main characteristics of the acetabular labrum can be seen in Table 1.

Table 1.
Dimensions Analysis of Acetabular Labrum

| Analysis | |
|--------------|-------------------------|
| Volume | 3958.45 mm ³ |
| Surface Area | 3208.97 mm ² |
| Length | 46.9 mm |
| Width | 40.6 mm |
| Height | 25.50 mm |

4. Discussion

With the advancement of modern medicine, many diagnoses have become an integral part of surgical planning. Radiography, computed tomography, magnetic resonance imaging technologies are currently used. 3D printer technology offers us today that we will go one step further than these imaging devices. Orthopedic surgery faces difficulties such as bone fractures, bone deformations. Radiographs are used for surgical planning. But 2-dimensional images have limitations. Especially, minimally invasive surgery is insufficient in planning cases. These limitations come into play as a solution to 3D modeling. Screws or plaques can be tested surgically before the patient is implanted and can guide the surgeon. As well as bone fragmentation wounds of arterial intersection or close to the nerves that will guide surgeons in surgery (10). RMIT (Royal Melbourne Institute of Technology) University developed a spinal implant cage using a 3D printer for patients with severe back pain. This customized 3D implant was transported to the patient and the patient was in the third month, but did not encounter any problems (11).

Brown et al. evaluated the stereolithographic model for the correct use of the fixation plate and screw trajectories in cases with complex fractures of eight acetabulum. They reported that the model was an effective way of planning the preoperative planning and accurate planning of acetabular fractures. They said it helped reduce operation time and reduce

morbidity (12).

In the study of acetabular fracture performed by Takahiro and colleagues, they reported that non-cytotoxic, acrylic based photopolymer 3D printing model is useful in preoperative evaluation, planning and simulation, but also for educational purposes (13).

In a study by Kim et al., In order to understand the complex patoanatomy of the acetabular fracture with 3-dimensional acetabular models, the screw insertion sites were helpful in the proper planning of the trajectories of the reduction clamps (14)

Although there are many advantages of 3D printing technology, there are some limitations. Time is one of them. The production of a 3D printing model takes several hours. So it is not suitable for emergencies. The fact that this is a new technology leads to material limitations and the disadvantage of being costly (15)

Patient-specific anatomical models enhance surgeons anatomical navigation knowledge about traumatized bones. 3D models are now routinely used even for complex surgeries. New surgeons can be used for training in surgeries requiring complicated surgery such as acetabular trauma. The model can also be examined intraoperatively by sterilizing. Preoperative examination of the 3-D model has advantages for surgeons. They help predict intraoperative difficulties, choose an optimal surgical approach with ease in implant placement planning and visualization of the pelvic screw orbit (14).

5. Conclusion

Considering the recent studies, attention to 3D printing is increasing in orthopedic surgery. It provides surgical guidance for surgeons and safe surgery for the patient for specific treatment. 3D modeling sheds light on future research in trauma and orthopedic cases (16).

In this technical note, we have shown that 3D printing is a highly relevant and useful technology from a clinical point of view for treating complex geometries as anatomy. Its cost and assumed complexity should not be obstacles to using this technology.

REFERENCES

1. Use of 3-Dimensional Printing for Preoperative Planning in the Treatment of Recurrent Anterior Shoulder Instability. Sheth U, Theodoropoulos J, Abouali J. 2015, Arthrosc Tech., s. e311-6.
2. Gradient-recalled echo sequences in direct shoulder MR arthrography for evaluating the labrum. Lee MJ, Motamedi K, Chow K, Seeger LL. 2008, Skeletal Radiol, s. 37:19-25.
3. Rapid prototyping in the assessment, classification and preoperative planning of acetabular fractures. Hurson C, Tansey A, O'Donnchadha B, Nicholson P, Rice J, McElwain J. 2007, Injury, s. 38:1158-62.
4. The effect of an acetabular labral tear, repair, resection, and reconstruction on hip stability to distraction. Nepple JJ, Philippon MJ, Campbell KJ, et al. The hip fluid seal. 2014, Knee Surg Sports Traumatol Arthrosc, s. 22:730-736.
5. The role of the acetabular labrum and the transverse acetabular ligament in load transmission in the hip. Konrath GA, Hamel AJ, Olson SA, Bay B, Sharkey NA. 1998, J Bone Joint Surg [Am], s. 80-A:1781-1788.
6. Fabrication procedure for cranial prostheses. Dumbrigue HB, Arcuri MR, LaVelle WE, Ceynar KJ. 1998, J Prosthet Dent, s. 79:229-231.
7. Cranioplasty using polymethyl methacrylate implant constructed from an alginate impression and wax elimination technique. Abdulai A, Iddrissu M, Dakurah T. 2006, Ghana Med J., s. 40(1):18-21.
8. Texto de Cirugía Plástica, Reconstructiva y Estética. Barcelona: Salvat Editores. Roa TT. Materiales inertes. In: En Coiffman F. 1986, s. 805-808.
9. Eufinger H, Saylor B. . implants, Computer-assisted prefabrication of individual craniofacial. 2001, AORN J., s. 74:648-654.
10. 3D printing: clinical applications in orthopaedics and traumatology . Auricchio F, Marconi S. 2016, s. 1:121-7.
11. Joint effort produces Australia's first 3D printed spine implant. [Çevrimiçi] 2019 . [Alıntı Tarihi: 24 May 2019.] <https://www.rmit.edu.au/news/all-news/2015/august/australias-first-3d-printed-spine-implant>.
12. Application of computer-generated stereolithography and interpositioning template in acetabular fractures: a report of eight cases. Brown GA, Milner B, Firoozbakhsh K. 2002, J Orthop Trauma, s. 16:347-52.
13. Tactile surgical navigation system for complex acetabular fracture surgery. Niikura T, Sugimoto M, Lee SY, Sakai Y, Nishida K, Kuroda R, et al. 2014, Orthopedics, s. 37:237-42.
14. 3D printing and its applications in orthopaedic trauma: A technological marvel. Lal H, Patralekh MK. 2018, Journal of Clinical Orthopaedics and Trauma, s. 9:260-8.
15. Use of 3-Dimensional Printing for Preoperative Planning in the Treatment of Recurrent Anterior Shoulder Instability. Sheth U, Theodoropoulos J, Abouali J. 2015, Arthrosc Tech., s. 4:e311-6.
16. Publication trends and knowledge mapping in 3D printing in orthopaedics. Vaishya R, Patralekh MK, Vaish A, Agarwal AK, Vijay V. 2018, J Clin Orthop Trauma, s. 9:194-201.